


# Journal Pre-proof

First report of monkeypox in a patient living with HIV from Romania

Cristiana Oprea, Irina Ianache, Sebastian Piscu, Gratiela Tardei, Maria Nica, Emanoil Ceausu, Corneliu Petru Popescu, Simin Aysel Florescu



PII: S1477-8939(22)00141-7

DOI: <https://doi.org/10.1016/j.tmaid.2022.102395>

Reference: TMAID 102395

To appear in: *Travel Medicine and Infectious Disease*

Received Date: 20 June 2022

Accepted Date: 22 June 2022

Please cite this article as: Oprea C, Ianache I, Piscu S, Tardei G, Nica M, Ceausu E, Popescu CP, Florescu SA, First report of monkeypox in a patient living with HIV from Romania, *Travel Medicine and Infectious Disease* (2022), doi: <https://doi.org/10.1016/j.tmaid.2022.102395>.

This is a PDF file of an article that has undergone enhancements after acceptance, such as the addition of a cover page and metadata, and formatting for readability, but it is not yet the definitive version of record. This version will undergo additional copyediting, typesetting and review before it is published in its final form, but we are providing this version to give early visibility of the article. Please note that, during the production process, errors may be discovered which could affect the content, and all legal disclaimers that apply to the journal pertain.

© 2022 Elsevier Ltd. All rights reserved.

**Title:**

First report of monkeypox in a patient living with HIV from Romania

**Authors:**

Cristiana Oprea<sup>1,2</sup>, Irina Ianache<sup>2</sup>, Sebastian Piscu<sup>2</sup>, Gratiela Tardei<sup>2</sup>, Maria Nica<sup>1,2</sup>, Emanoil Ceausu<sup>2,3</sup>, Corneliu Petru Popescu<sup>1,2</sup>, Simin Aysel Florescu<sup>1,2</sup>

1. Carol Davila University of Medicine and Pharmacy, Bucharest, Romania
2. Dr Victor Babes Clinical Hospital for Infectious and Tropical Diseases, Bucharest, Romania
3. Academia de Stiinte Medicale, Romania

**Corresponding author:**

Corneliu Petru Popescu, email: [cornel160@yahoo.com](mailto:cornel160@yahoo.com), address Dr Victor Babes Clinical Hospital of Infectious and Tropical Diseases, Sos Mihai Bravu 281, sector 3, Bucharest, Romania.

**Author's contributions**

We consider that all authors equally contributed on this manuscript.

**Keywords:**

Monkeypox virus, HIV, men having sex with men (MSM)

**Article type:**

Correspondence

Dear Editor,

On May 13, 2022, World Health Organization reported cases of infection due to monkeypox virus in 12 not endemic countries (1) and the outbreak reached 2,027 confirmed cases by 15 June 2022 in 36 countries (2). Monkeypox virus is a double-stranded DNA virus of the Poxviridae family, with a classic mode of transmission from infected animals to humans and less infectious

than smallpox virus between humans. Disease clusters of the current outbreak are known to include high risk groups as men who have sex with men (MSM) (3).

We present a case of a 26-year-old HIV-infected male, without history of travel, admitted to Dr Victor Babes Clinical Hospital for Infectious and Tropical Diseases, Bucharest, Romania, with high fever (up to 39 Celsius degrees), chills, rectal pain, vesiculo-pustular rash and dysphagia. He was diagnosed with HIV infection in 2019, with a CD4 cell count of 546/ $\mu$ L and an HIV viral load of 46.000 copies/mL, acquisition was by sexual contact (MSM). His medical history was unremarkable, excepting surgery for an anal fissure 4 years ago. He initiated antiretroviral treatment with 3TC/ABC/DTG and is adherent.

The patient admitted that he was involved in CHEMSEX practices in the past history, but not prior to the onset of the current condition which began 4 days before the admission. To mention that, in addition to the presenting symptoms, the papular and vesicular rash, initially localized on the penile area spread to the perianal, anal and rectal area and that the patient reported severe pain in the ano-rectal region.

On examination a vesicular and pustular rash was seen, predominantly ano-genital and on the buttocks, with a few lesions on the neck, trunk and upper and lower limbs and one lesion on the sole of a foot. Lesions were well defined, deep seated, some of them with an umbilicate aspect. (Figure 1, 2). He also presented marked hyperemia of the pharynx, with pseudo-membranous appearance, and palatine petechiae, thrush, enlarged cervical and inguinal lymph nodes. The patient was afebrile, vital signs were normal and no other clinical abnormalities were observed. There were no lesions on the oral mucous membranes or conjunctiva.

Blood diagnostics showed a slight increase of white blood cell count (10200/ $\text{mm}^3$  with a monocytosis and a mild inflammatory syndrome (CRP 2.14 mg/dL). CD4 count was 988/ $\mu$ L and HIV-1 viral load in plasma was detected below 40 copies/mL. Serology tests for syphilis, viral hepatitis B and C were all negative and the chest X ray was normal. Real time PCR test for MPXV was positive in different biological sample types, with lower Ct values in the vesicular fluid from the skin lesions, followed by samples from nasopharyngeal swabs, urine and blood.

We used a Research Use Only (RUO), commercially available Monkeypox virus (MPXV) real time PCR test designed and manufactured in Romania by Molecular Genomics, Bragadiru, starting from AF380138.1 MPXV genome and a previously published method (4). In brief, viral

DNA was obtained through automated extraction with MagNA Pure 96, Roche and MagNA Pure 96 DNA and Viral NA SV kit, from 200 uL of vesicular fluid diluted in viral transport medium. The elution volume was 50 uL and 5 uL of DNA was added to 15 uL of Master Mix plus primers and probes mixture according to the manufacturer's instructions. Real-time PCR amplification was performed on a CFX96 Real-Time System, Bio-Rad. The test has two viral targets located in two viral ORF's (F3L and N3R), detected by two different fluorescence channels and one target as internal control (the human RNase P).

He received symptomatic treatment, fluids and topic treatment for thrush and pharyngeal hyperemia. The evolution was favorable, until the submission of the report, despite coinfection with HIV, as the patient had a good immunological status. Fever and chills subsided after 2 days from onset and the skin lesions followed the common pattern with evolution from papules to pustules, with relatively the same size and same stage of development at different parts of the body.

This is the first case of monkeypox confirmed in Romania, with suggestive epidemiological and clinical features. He developed a mild form of the disease, with skin lesions evolving predominant in the ano-genital area. It is important to raise awareness for the transmission of monkeypox, especially in populations with high risk factors. Public health authorities and clinicians must consider the diagnosis of monkeypox in all patients with typical rash and risky sexual behavior, in particular in those with recent sexual contacts with partners who traveled in countries with reported cases of monkeypox or partners with the same clinical manifestations even if they do not traveled in other countries.

### **Funding**

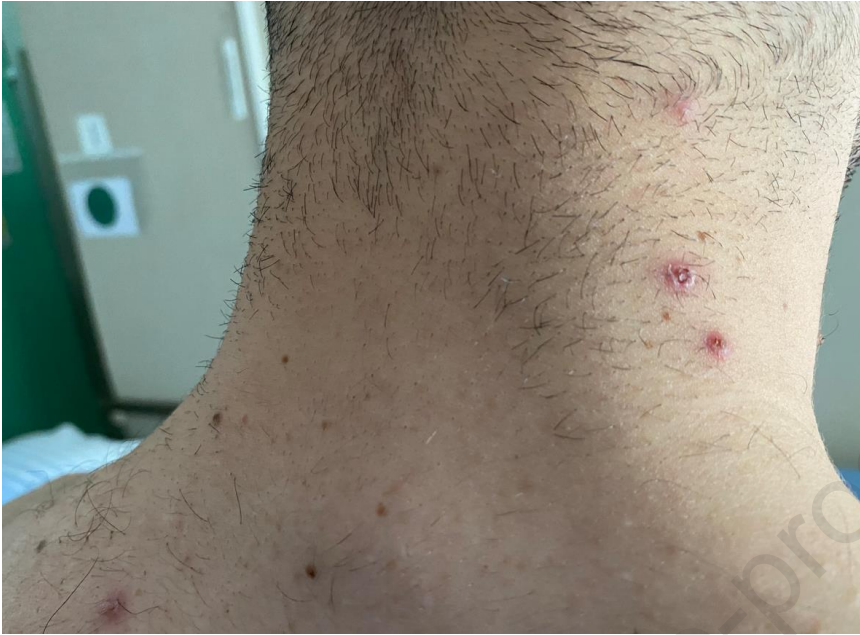This research did not receive any specific grant from funding agencies in the public, commercial, or not-for-profit sectors.

### **Declaration of competing interest**

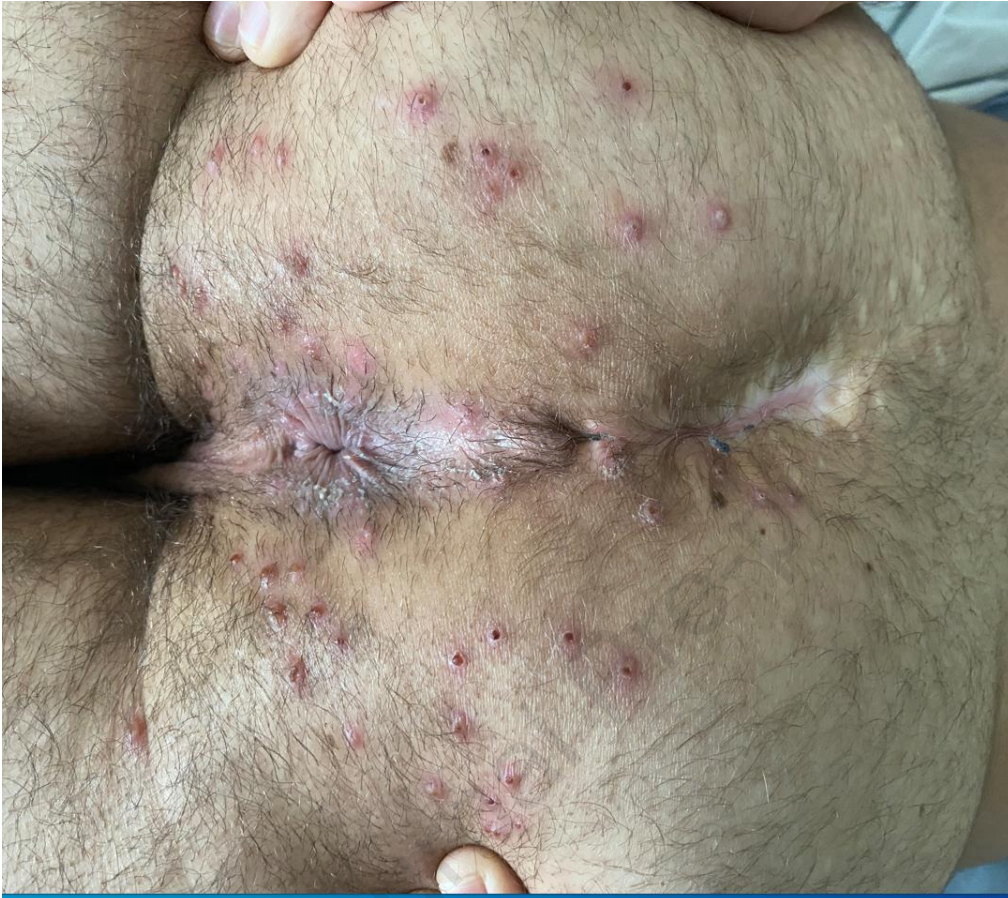Nothing to declare.

**References:**

1. Multi-country monkeypox outbreak in non-endemic countries. Accessed June 16, 2022. <https://www.who.int/emergencies/disease-outbreaknews/item/2022-DON385>
2. 2022 Monkeypox and Orthopoxvirus Outbreak Global Map, Accessed June 16, 2022. <https://www.cdc.gov/poxvirus/monkeypox/response/2022/world-map.html>
3. León-Figueroa DA, Bonilla-Aldana DK, Pachar M, Romaní L, Saldaña-Cumpa HM, Anchay-Zuloeta C, Diaz-Torres M, Franco-Paredes C, Suárez JA, Ramirez JD, Paniz-Mondolfi A, Rodriguez-Morales AJ. The never-ending global emergence of viral zoonoses after COVID-19? The rising concern of monkeypox in Europe, North America and beyond. *Travel Med Infect Dis.* 2022 May 26;49:102362. doi: 10.1016/j.tmaid.2022.102362. Epub ahead of print. PMID: 35643256; PMCID: PMC9132678.
4. Kulesh, D., Loveless, B., Norwood, D. *et al.* Monkeypox virus detection in rodents using real-time 3'-minor groove binder TaqMan<sup>®</sup> assays on the Roche LightCycler. *Lab Invest* **84**, 1200–1208 (2004). <https://doi.org/10.1038/labinvest.3700143>



**Figure 1** Pustular lesions with umbilicate aspect on the neck in a young MSM with Monkeypox



**Figure 2** Pustular and vesicular rash in the ano-genital area and on the buttocks in a young MSM with Monkeypox